



PATIENT SPOTLIGHT

TORS for the Unknown Primary

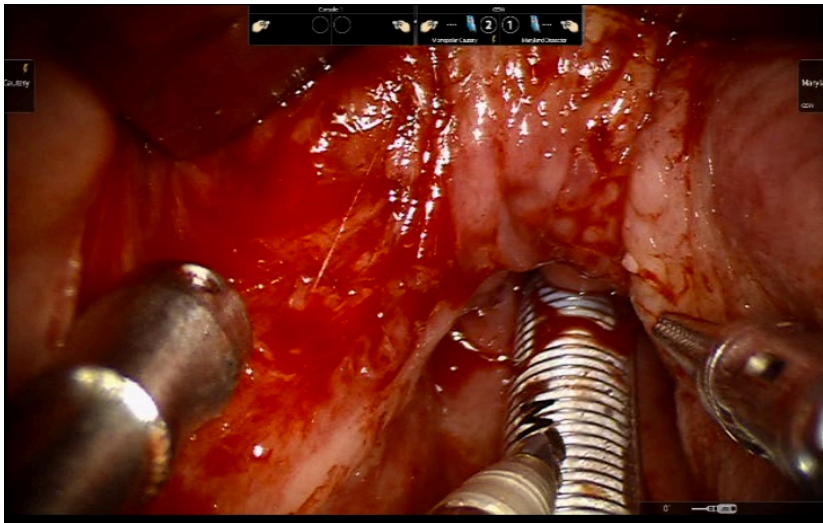


Fig 1 - Exposure of the left base of tongue prior to robotic-assisted lingual tonsillectomy

A 40 year old man is seen in the office complaining of a one month history of a cystic left-sided neck mass.

CLINICAL SIGNS

On exam, a left sided neck mass was observed. He is a life-long non-smoker. Fine-needle aspiration (FNA) at an outside institution was inconclusive, but an excisional lymph node biopsy revealed a 2.5 cm HPV-positive squamous cell carcinoma. Staging PET-CT did not reveal a primary cancer.

CLINICAL FINDINGS

For this particular patient, a novel transoral robotic approach to perform a palatine and lingual tonsillectomy for primary identification was used as these HPV positive tumors are almost always located in the lymphatic tissue surrounding the oropharynx. A lateralized 1 cm base of tongue primary was identified and resected to negative margins. An ipsilateral level II-IV selective neck dissection was performed and did not identify any additional neck metastases. Thus, with pathologic staging of T1N1, he was able to completely avoid chemotherapy and radiation. No complications were noted and the patient was swallowing with a soft diet on postoperative day number 1.



ENT and Allergy
Associates, LLP

This patient was
referred by a tri-state
ENTA physician.

Our shared EHR
facilitates a seamless
referral process and
transfer of medical
records with the push of
a button.

To refer a patient:

Call us direct at
Physician Access Services
(212) 241-4983

*Thank you for your
referrals.*

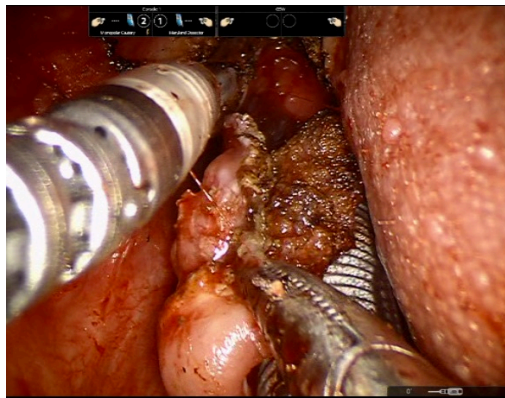


Fig 2 - Lingual tonsillectomy specimen being removed from the surgical field

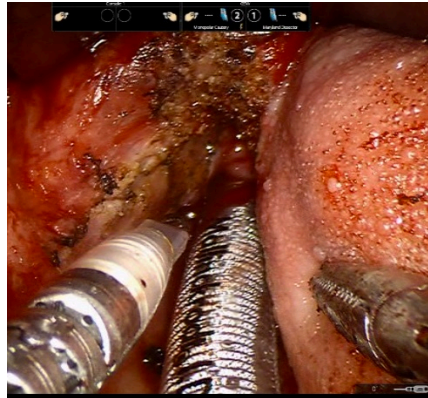


Fig 3 - Final defect after lingual tonsillectomy.

**MOUNT SINAI
HEALTH SYSTEM
ROBOTIC SURGERY
TEAM**

Mount Sinai Campus

Eric M. Genden, MD
Chairman
Head and Neck Cancer

Fred Y. Lin, MD
Sleep Surgery

Brett A. Miles, DDS, MD
Head and Neck Cancer

Marita S. Teng, MD
Head and Neck Cancer

Mike Yao, MD
Head and Neck Cancer

Manhattan Offices:

Faculty Practice Associates
5 East 98th Street, 8th Floor
New York, NY 10029

Center for Science and Medicine
10 East 102nd St, 3rd Floor
New York, NY 10029

Beth Israel Campus

Raymond Chai, MD
Head and Neck Cancer

Neil Gildener-Leapman, MD
Head and Neck Cancer

Manhattan Office:

10 Union Square East, Suite 5B
New York, NY 10003

Brooklyn Office:

9020 5th Ave, 3rd Floor
Brooklyn, NY 11209

DISCUSSION

There is a rising epidemic of HPV-related oropharyngeal cancer that is largely unknown to the public, with over 10,000 cases in the United States each year. By 2020, the number of HPV-driven head and neck cancers is expected to exceed that of cervical cancer. Although survival for these cancers is excellent compared to tobacco-driven malignancies, the current standard treatment of radiation with chemotherapy has many potential toxicities, both acute and long-term.

With this epidemic, there is a rising proportion of patients that initially present with neck metastases in which a primary tumor is unable to be detected on either clinical examination or imaging. Identifying the primary tumor critical for these patients and can decrease morbidity by either limiting the volume of the radiation field, excluding chemotherapy, or allowing select patients to completely forgo radiation therapy. The traditional method of detection consists of examination under anesthesia, tonsillectomy, and directed biopsies localizing the primary in only 17-40% of cases. At Mount Sinai, we utilize a novel transoral robotic approach to perform a palatine and lingual tonsillectomy for primary identification as these HPV positive tumors are often in the lymphatic tissue surrounding the oropharynx. If a primary is identified, it is resected to negative margins. This approach has been demonstrated in multiple series to identify the primary in roughly 90% of patients. Morbidity is minimal and most patients are discharged the day following surgery. At Mount Sinai Beth Israel, we offer a special expertise in the use of transoral robotic surgery as a minimally invasive approach to the resection of head and neck cancer. All robotics cases are performed with two attending surgeons present to allow for maximum efficiency and patient outcomes.



By Raymond Chai, MD
Assistant Professor
Department of Otolaryngology
Director of Head and Neck Robotic
Surgery, Mount Sinai Beth Israel

and



Neil Gildener-Leapman, MD
Assistant Professor
Department of Otolaryngology
New York Eye and Ear Infirmary of Mount
Sinai